

RESPIRATORY DISORDERS IN FARMED RABBITS. 1996-2020. IMAGES

Juan María Rosell Pujol, DVM PhD. e-mail: jmrosellp@cunivetservice.com 27 April 2022



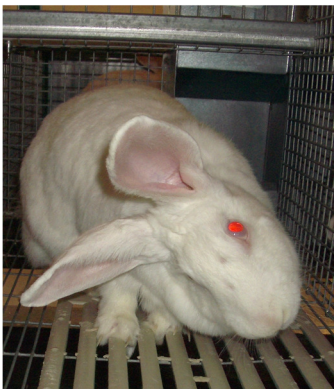Environmental control is essential to have healthy farmed rabbits



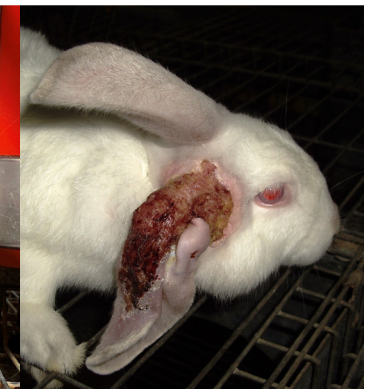Control is time consuming. It requires attention (e.g., twice daily), experience, and occasionally: technical support



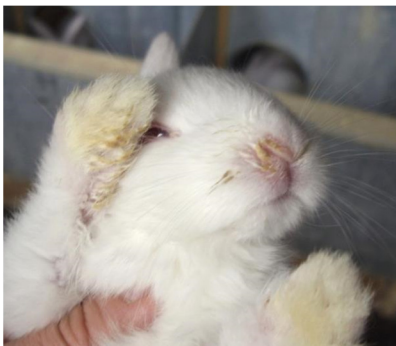Several devices can be used to have objective information



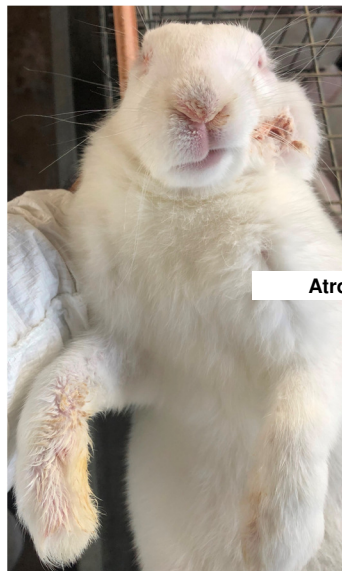There are clinical signs of great interest, such as sneezing (rabbits do not cough), conjunctivitis, torticollis, and respiratory distress



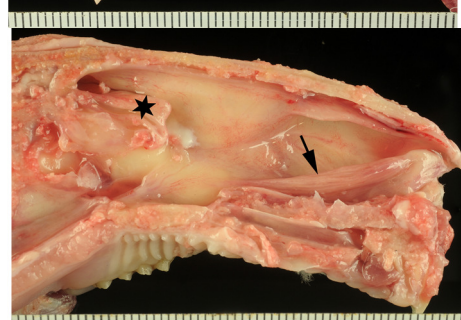
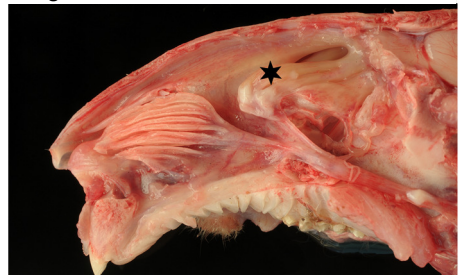
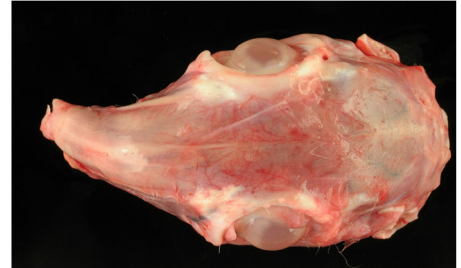
There are lesions compatible with diseases of the respiratory system, such as abscesses (abdominal region or throat) and external otitis



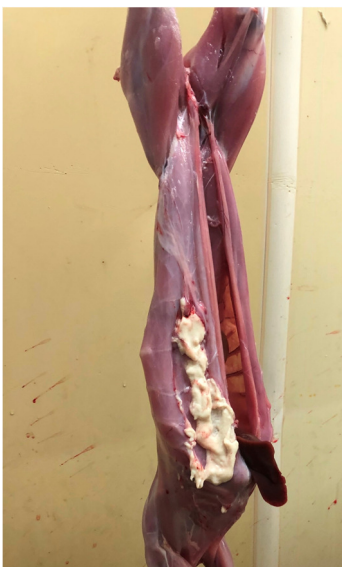Rhinitis affects kits, growers and adults



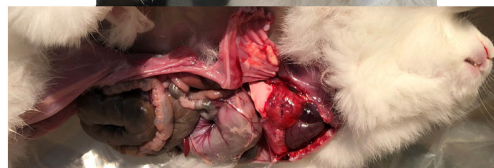Atrophic rhinitis might affect weaned rabbits and adults



Images of atrophic rhinitis, courtesy of Dr. D. Fernández de Luco and Dr. M. C. Arnal



Lesions at abattoir inspection



Pneumonia due to *Pasteurella multocida* (confirmed), in siblings 21 days old

