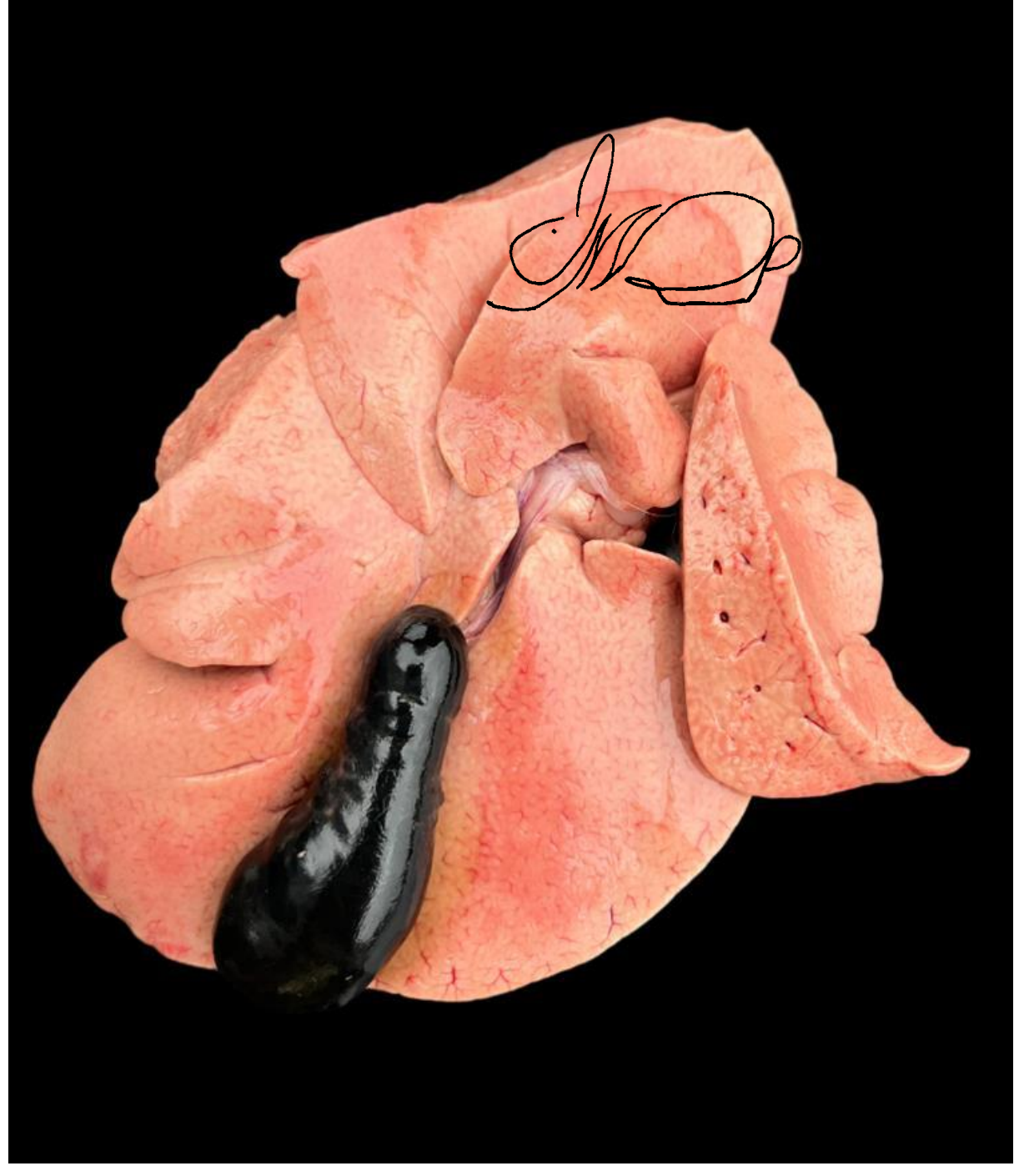
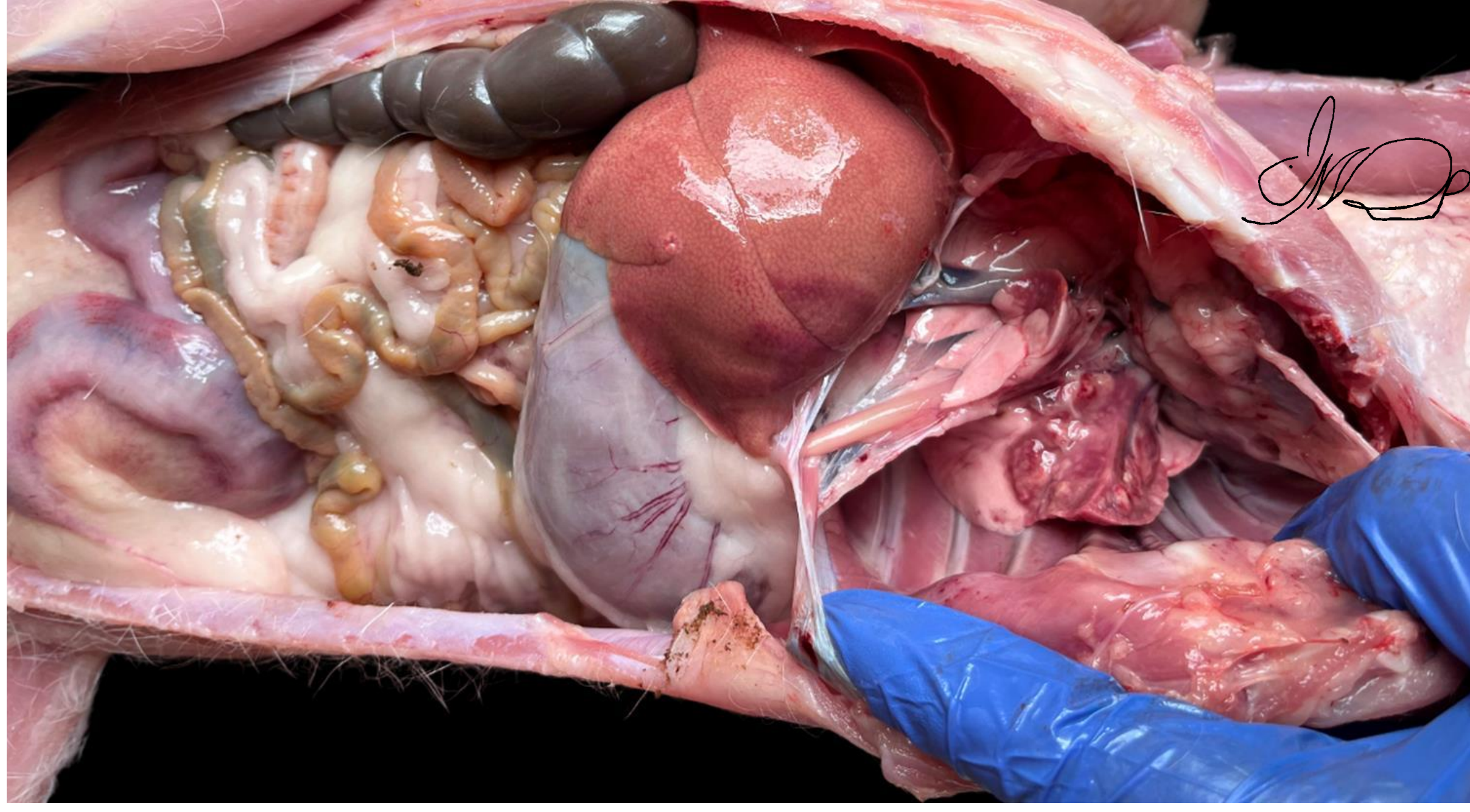


## FATTY LIVER IN FARMED RABBIT FEMALES. 1996 - 2023. IMAGES. LR

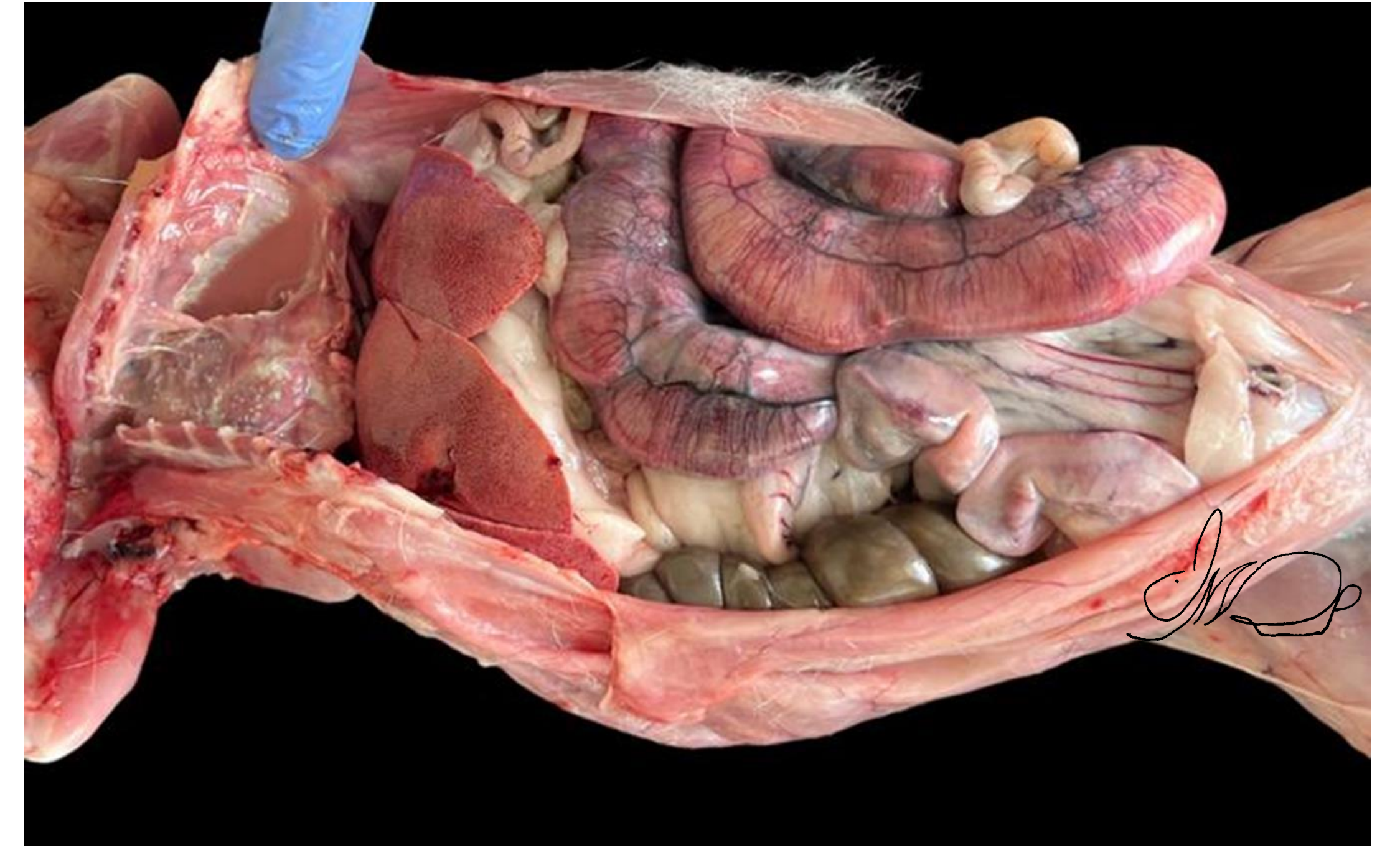Juan Maria Rosell Pujol, DVM PhD. E-mail: [jmrosellp@cunivetservice.com](mailto:jmrosellp@cunivetservice.com) July 2024



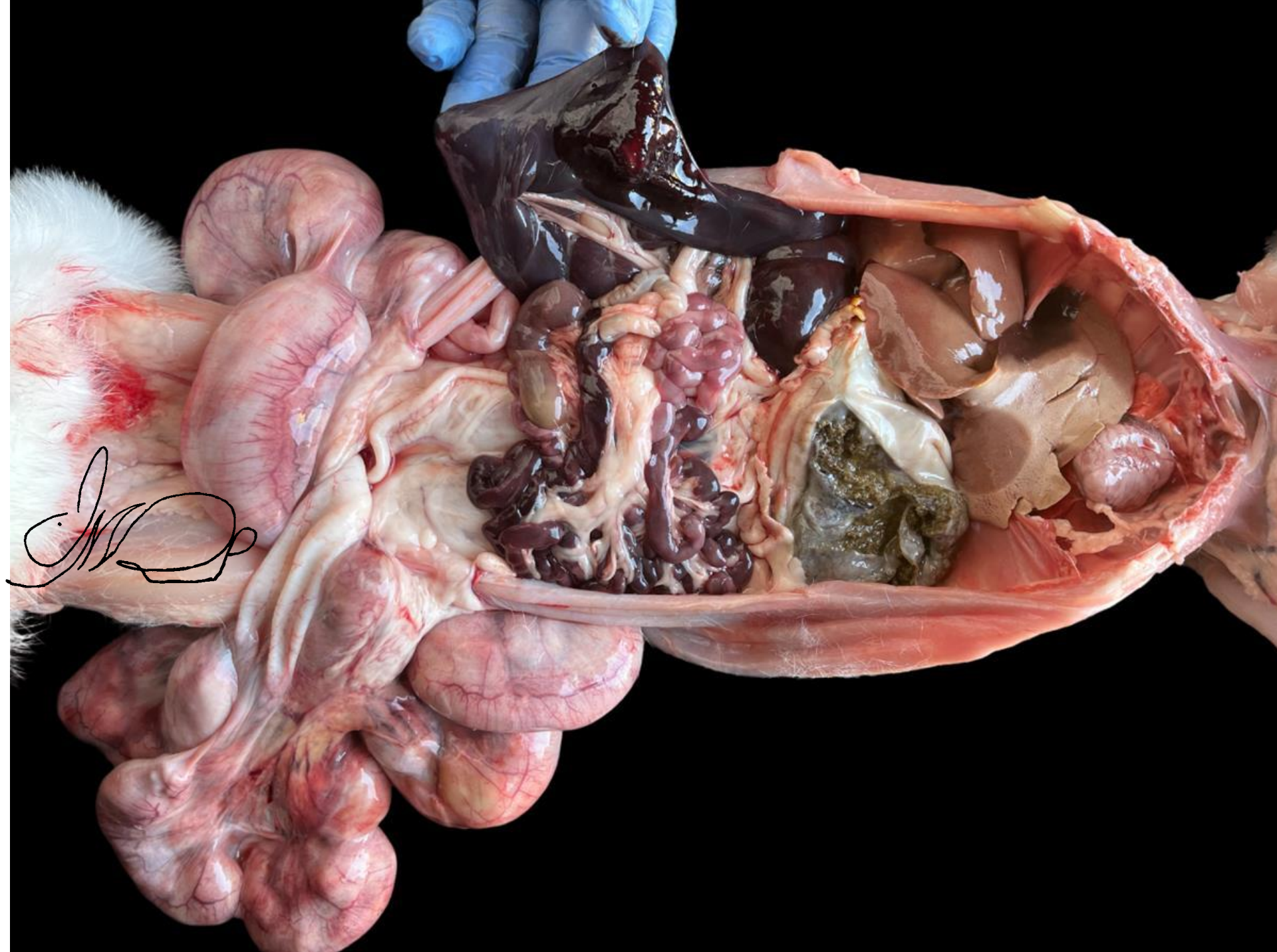
Fatty liver /FL



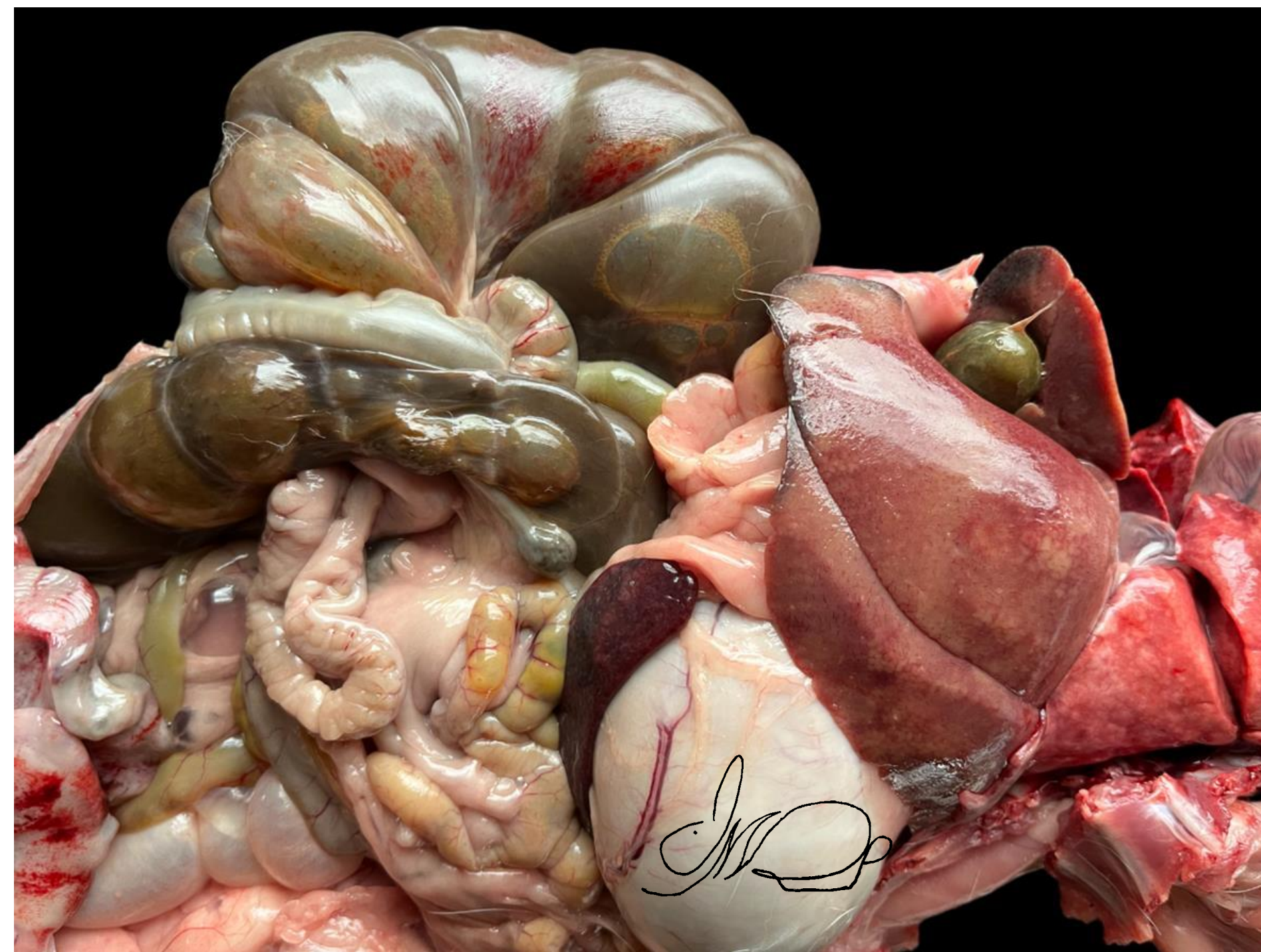
Pneumonia (pasteurellosis, confirmed) and FL. Aborted. Classified as *secondary pregnancy toxemia*



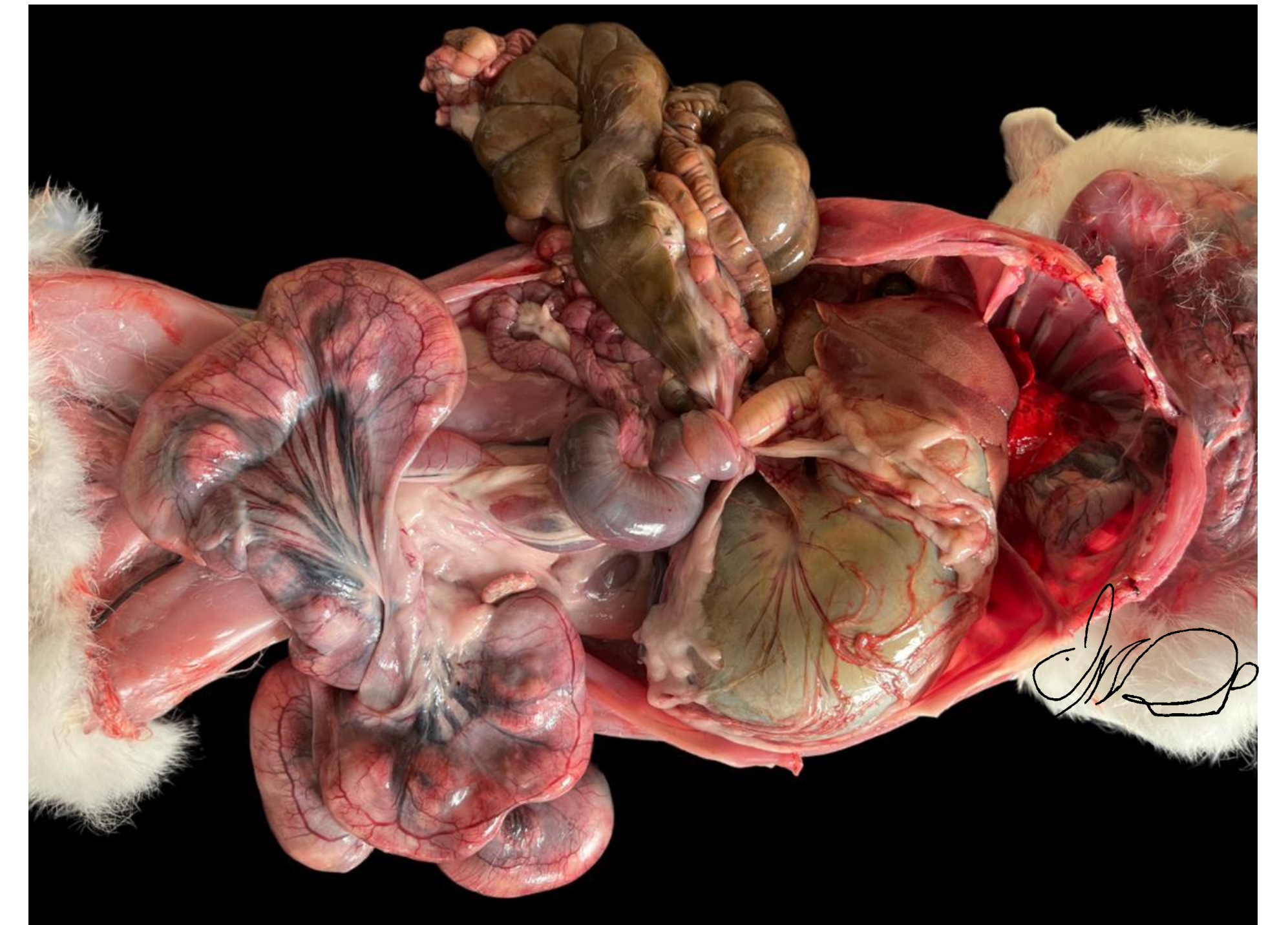
Fibrinous pneumonia and fatty liver, 30th d of pregnancy. Classified as *pneumonia*



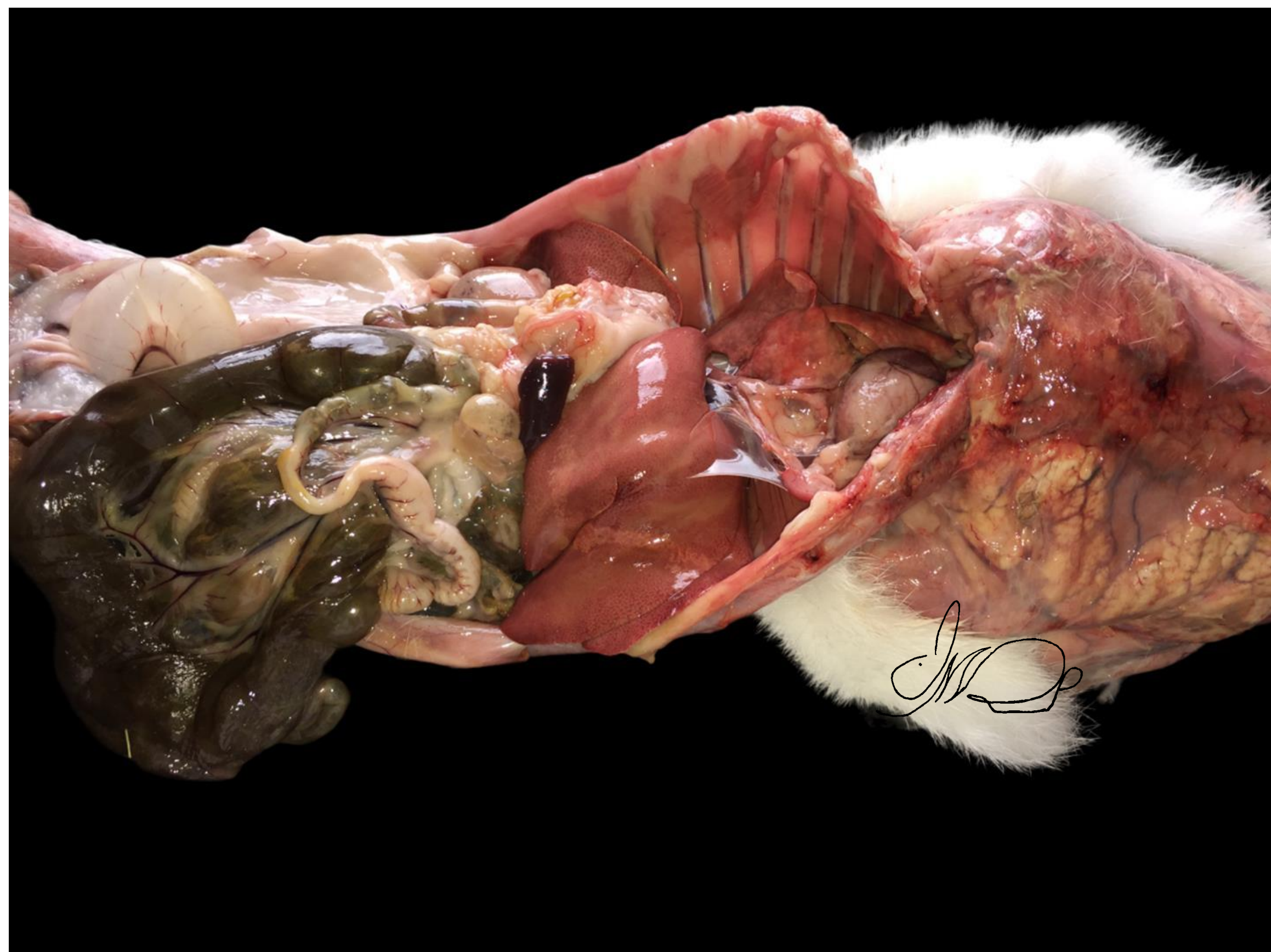
*Secondary pregnancy toxemia/ ketosis and enteritis*



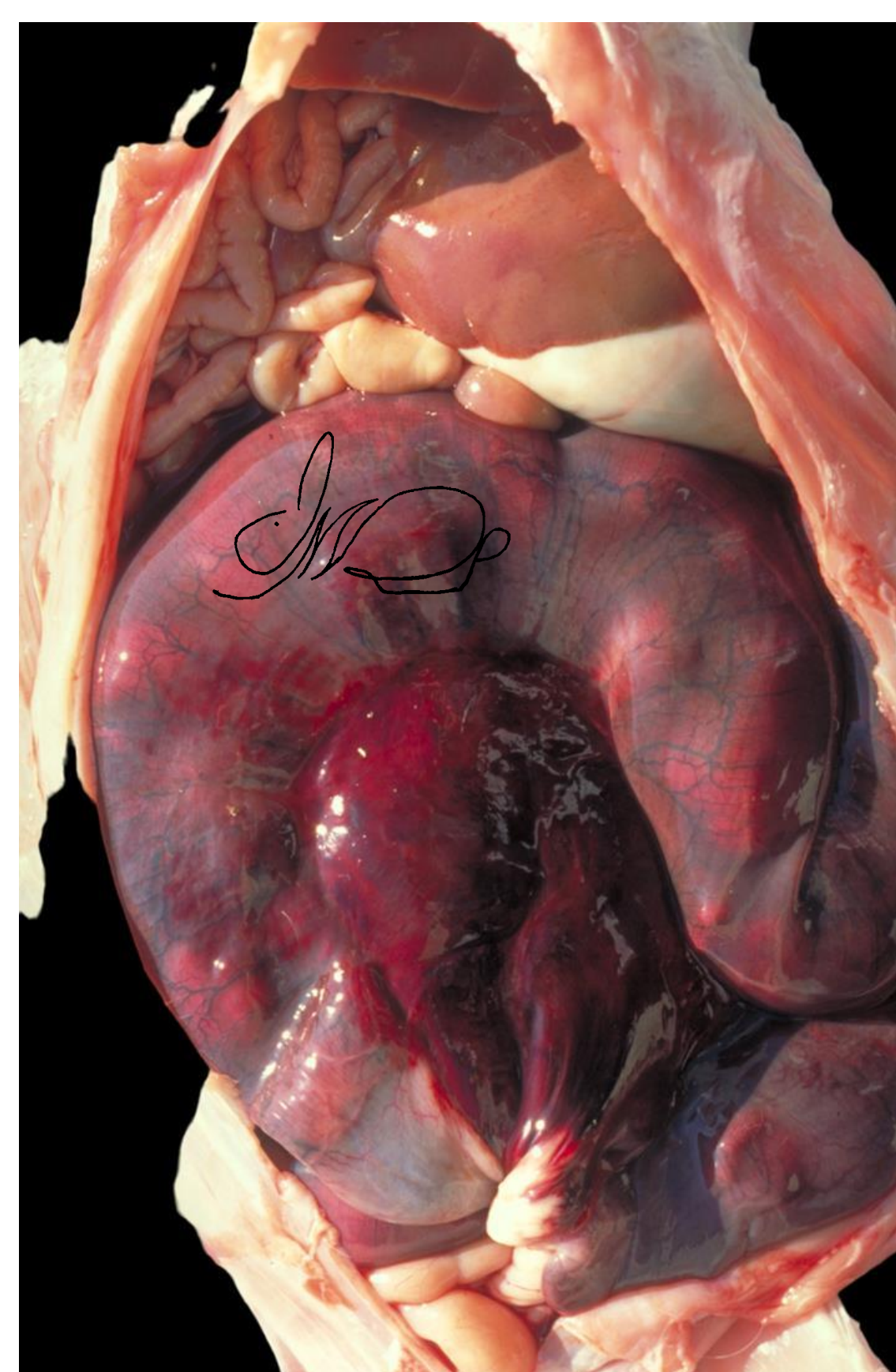
*Hemorrhagic septicemia due to salmonellosis (confirmed) and FL*



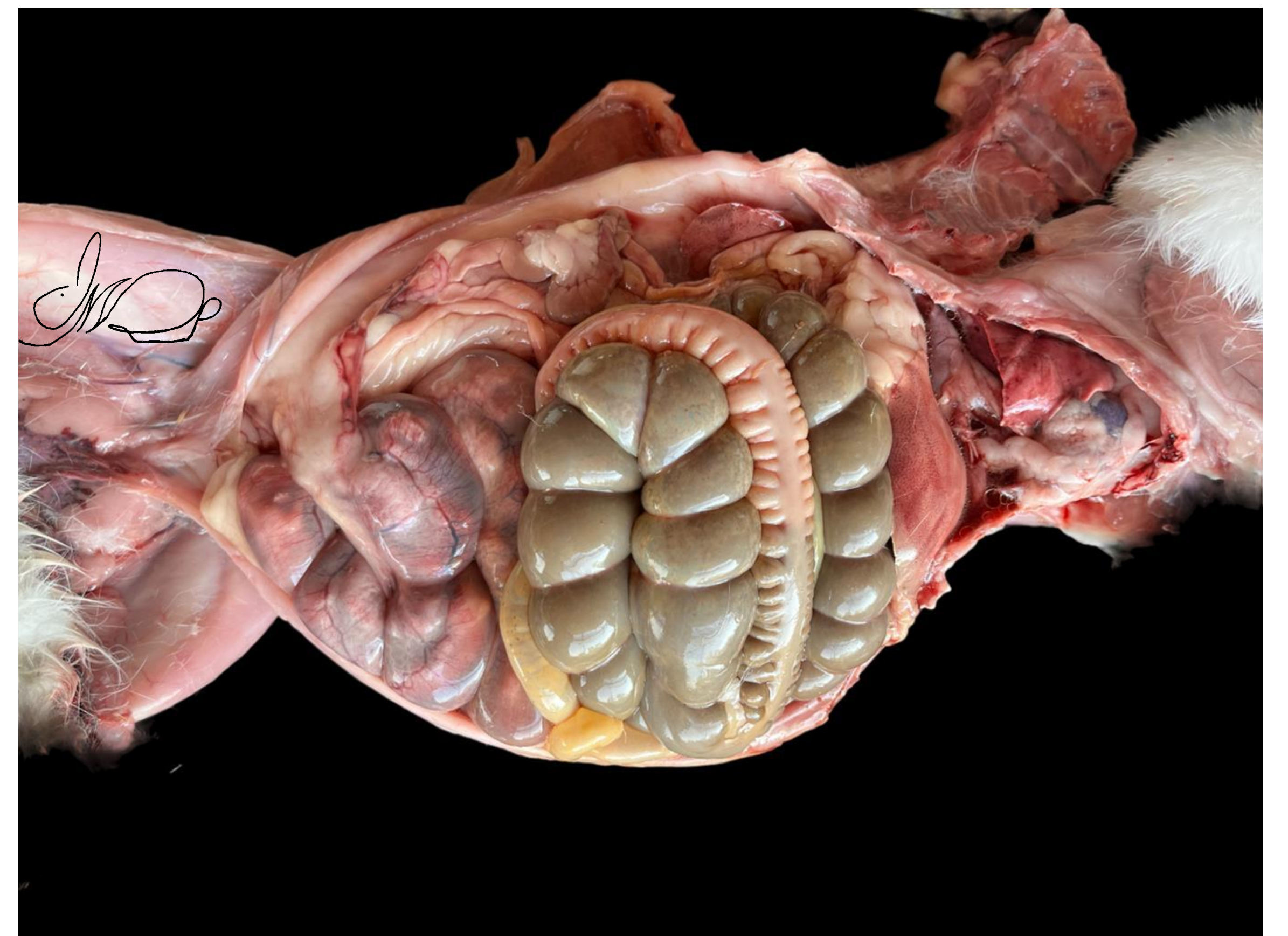
*Mucoid enteropathy/ME. Stomach with liquid and gas. Midgut volvulus and mucus. FL. Classified as ME case*



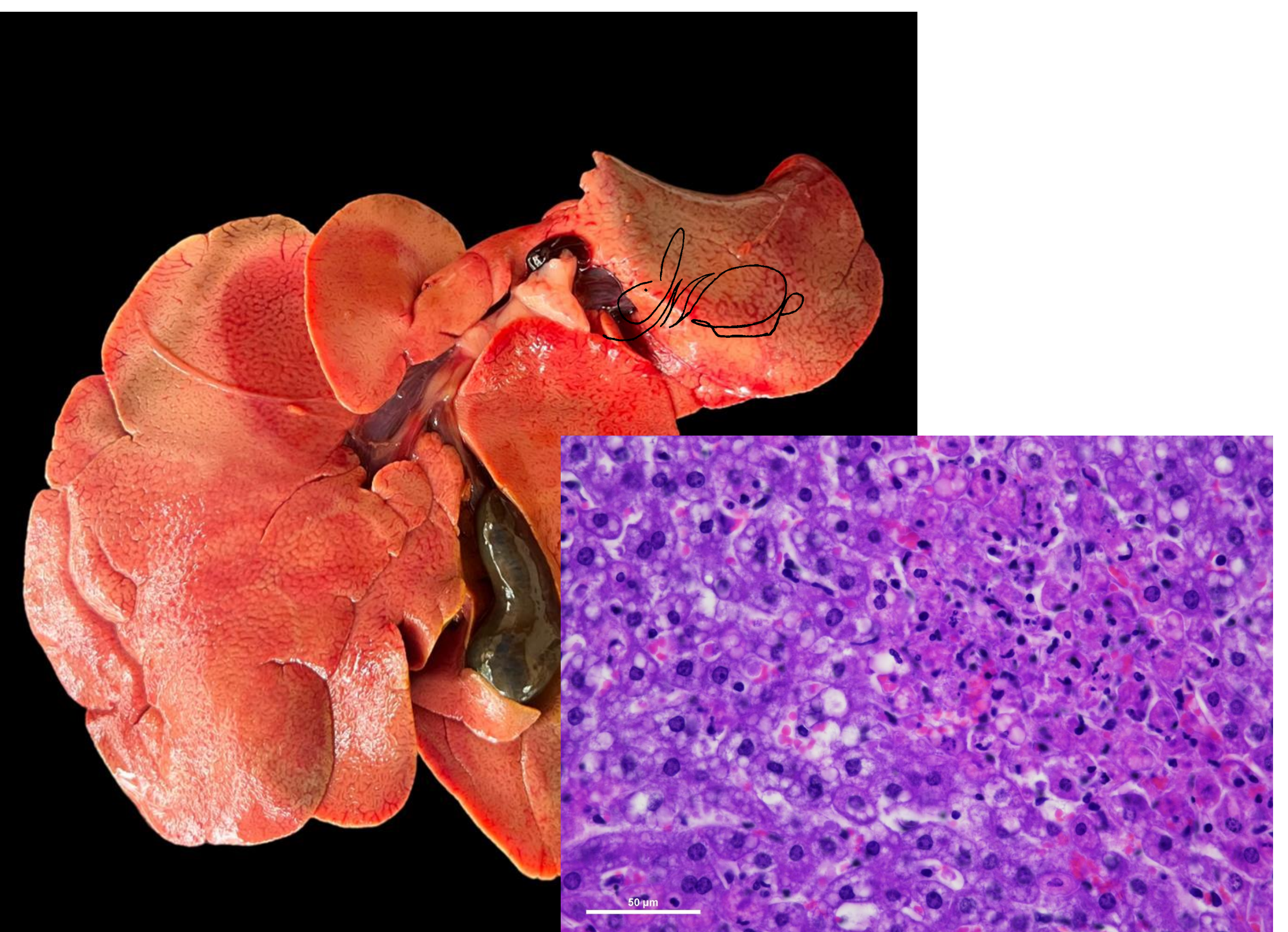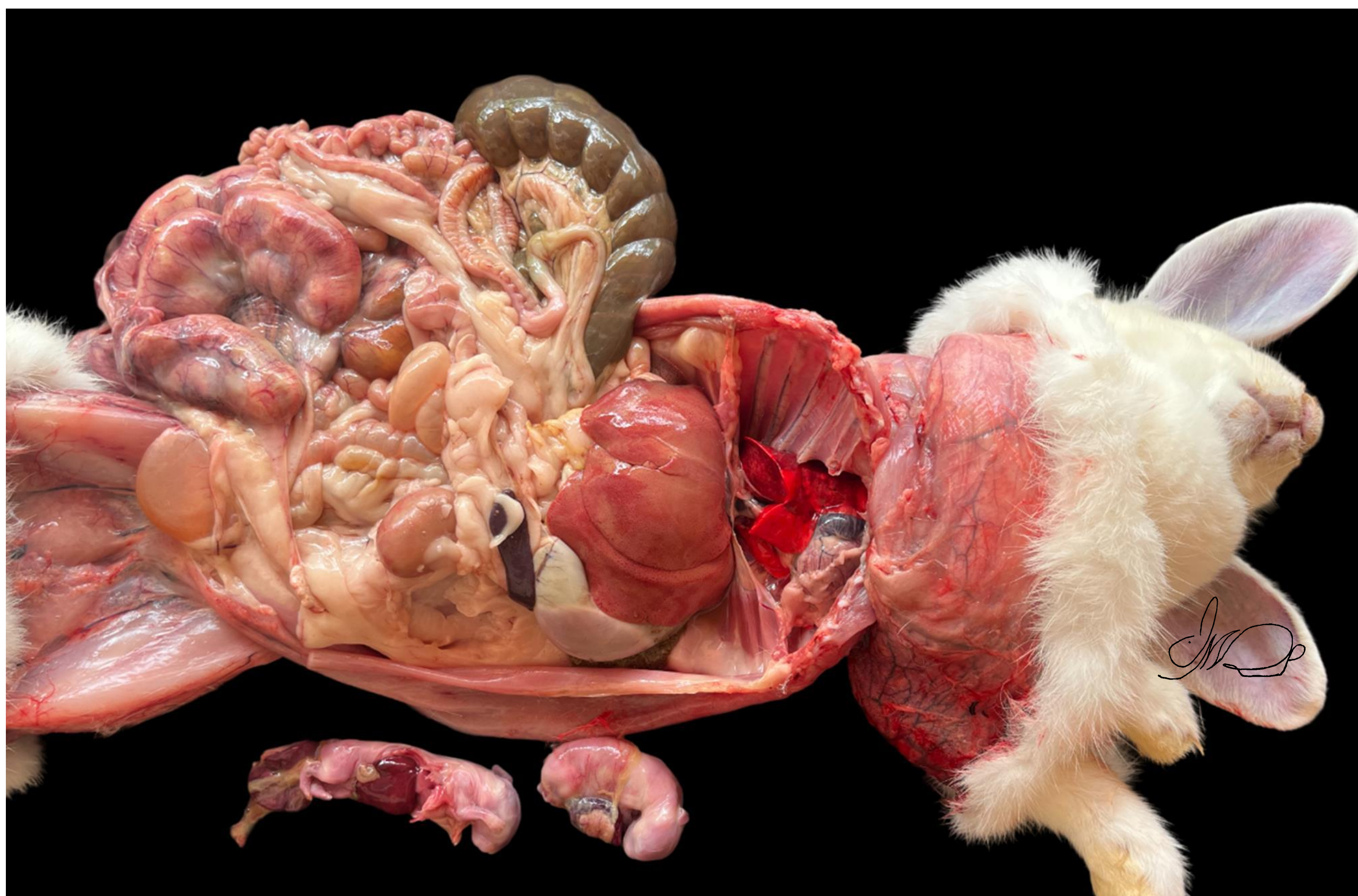
*Acute mastitis (Staphylococcus aureus confirmed) and fatty liver*



*Uterine torsion and FL*



*Heat stroke and fatty liver*




Steatotic-necrotic liver of a doe dead due to RHD. Pathological features courtesy of Dr. M.C. Ferreras. Virological assessment courtesy of Dr. K. P. Dalton

We visited a farm affected by RHD in weaned rabbits (confirmed: RHDVb). Furthermore, we necropsied a 1st pregnancy doe on her 27th day of gestation. We suspected death due to RHD, pregnancy toxemia, or both. We sent samples to Pathology and Microbiology labs. The results confirmed co-morbidity. *Necropsy classified as RHD*

[www.cunivetservice.com](http://www.cunivetservice.com)

Do not copy in publications or websites, please

  
Juan Maria Rosell Pujol